

# Primary Care Management of Snoring in Adults/ Sleep Apnoea

Patient information:

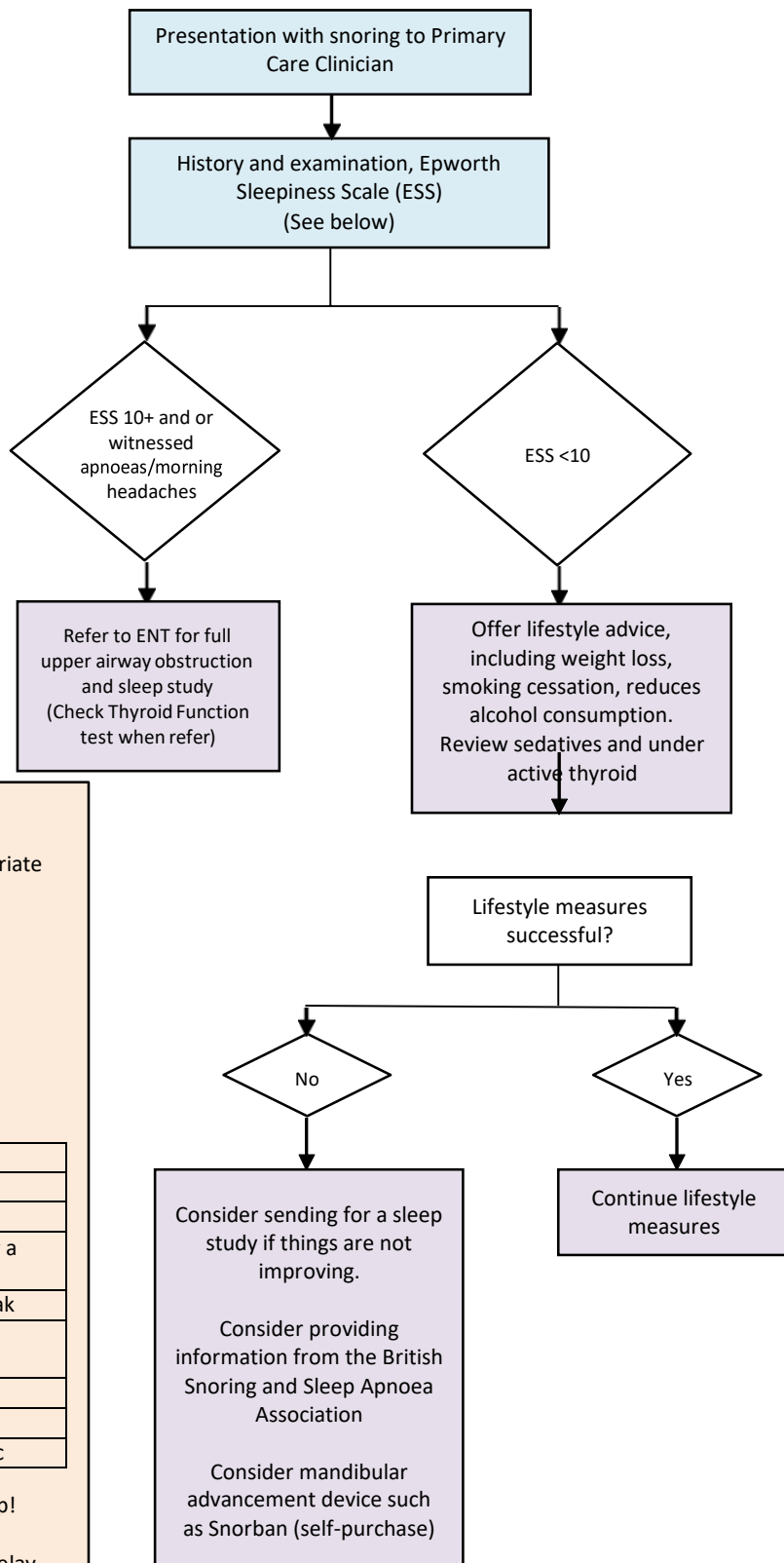
- [http://www.entuk.org/patient\\_info/throat/snoring.html](http://www.entuk.org/patient_info/throat/snoring.html)
- The British Snoring and Sleep Apnoea Association website at: [www.britishsnoring.co.uk](http://www.britishsnoring.co.uk)

**History, include:**

- Loudness of snoring
- Excessive/intrusive daytime sleepiness
- Witnessed apnoeas
- Impaired alertness
- Nocturnal choking episodes
- Waking unrefreshed
- Co-morbidity e.g. hypothyroidism, ischaemic heart disease, cerebrovascular disease, diabetes, hypertension
- Smoking history
- Alcohol consumption
- Medication history
- Consider psycho-social impact
- Morning headache

**Examination, include:**

- BMI
- Collar size
- Tonsil grade (refer to diagram)
- Pharynx (refer to diagram)
- Bite? Recessed mandible, under-projected maxilla



**Epworth Sleepiness Scale**

Use the following scale to choose the most appropriate number for each situation:

0 = No chance of dozing  
 1 = Slight chance of dozing  
 2 = Moderate chance of dozing  
 3 = High chance of dozing

SITUATION
Sitting and reading
Watching TV
Sitting, inactive in a public place (e.g. a theater or a meeting)
As a passenger in a car for an hour without a break
Lying down to rest in the afternoon when circumstances permit
Sitting and talking to someone
Sitting quietly after lunch without alcohol
In a car, while stopped for a few minutes in traffic

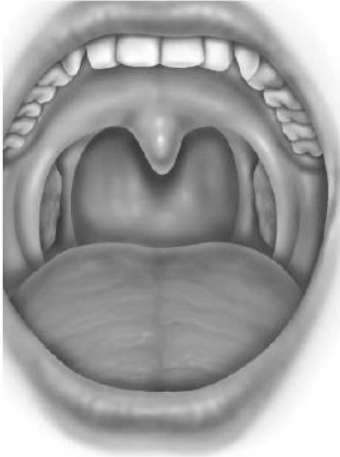
1-6 = Congratulations, you are getting enough sleep!  
 7-8 = Your score is average  
 9+ = Seek the advice of a sleep specialist without delay

# Clinical Examination of Snoring

## Tonsil Size: Graded 1 to 4

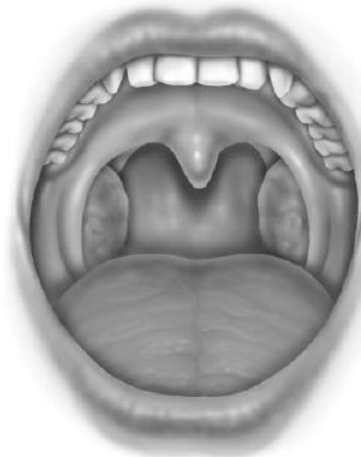Grade 1

Tonsils hidden within pillars



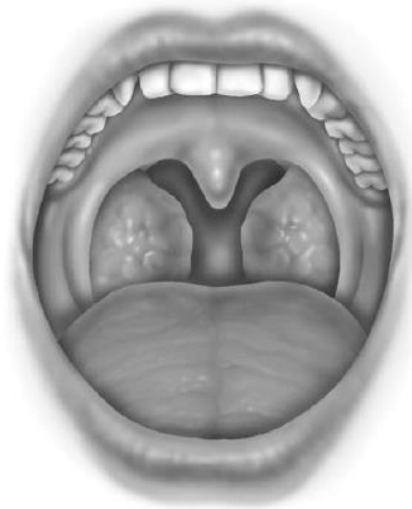Grade 2

Tonsils extend to edge of pillars



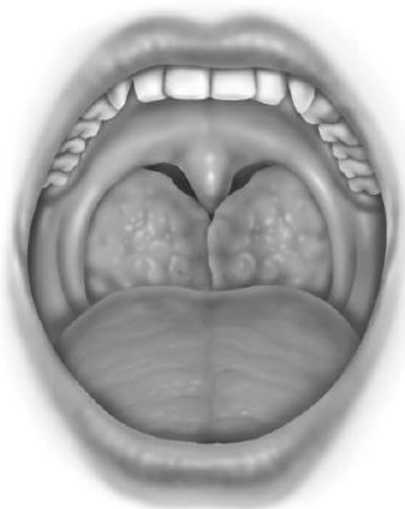Grade 3

Tonsils beyond pillars but not to midline



Grade 4

Tonsils meet in midline



## Snoring in Primary Care: Examination of the Pharynx (Malampatti)

A = Grade I: full view of oropharynx

B = Grade II: pillars still visible

C = Grade III: only base of uvula seen

D = Grade IV: tongue obscures whole oropharynx

